Osaka Prefecture University

Bull, Univ, Osaka Pref, Ser, B.
大阪府立大学紀要，農学・生物学 Vol: 21, 1969

Histological study of the pregnant uterus in the cow. II. General histological study on the uterine glands.

Shoji Yamauchi, Tomofumi Kakishita and Keiichi Kotera

Lab. of Vet. Anat., College of Agriculture

In contrast to the knowledge concerning a placentome, that of the intercotyledonary area in a bovine placenta is very limited. Previous papers by BJÖRKMAN,[1] HATCH[2] and PETKOV[3] are mainly concerned with the intercotyledonary placenta of the ruminant. Considerable variations are noted among literatures with respect to the time of attachment of the bovine blastocyst to the endometrium, which varies between 12th day and 3rd month after fertilization. It is well known that the paraplacenta relates, exclusively, to the nourishment to the developing fetus. So-called 'uterine milk' has been considered to consist of uterine secretions (from both surface and glandular epithelia), migrated blood cells and tissue detritus mainly derived from the epithelium, and which nourishes the fetus both before and after its attachment to the uterus.[4,5,6]

AMOROSO[4] suggested that the substantial importance of the uterine milk varies according to the different stage of pregnancy as well as to the different type of placentation in mammals. DUKES[7] emphasized the importance of uterine milk in the nutrition of the bovine embryo early in pregnancy but he stated that this function ceases in late pregnancy. FOLEY and REECE[8] stated that uterine glands seem to be important at least up to the end of 4th month of pregnancy. According to WEETH and HERMAN[9] the uterine glands seem to secrete actively during pregnancy with some decrease in activity being noted in late pregnancy. On the other hand, PETKOV[3] and WIMSATT[10] found in a sheep uterus, respectively, that the glands continue to proliferate and hypertrophy during pregnancy even to term. The extent and character of the growth of glands in a cow uterus during pregnancy are matters of confliction (see HATCH[2] and WEETH and HERMAN,[9] for example).

Previously, present authors published the paper entitled "Histological study of the pregnant uterus in the cow. I. General histology of the intercaruncular endometrium".[11] In a present paper, histological findings on uterine glands during pregnancy will be descrided and the significance of the secretion from uterine glands will be discussed.

Materials and Methods

Materials used in this study are the same as those included in a previous paper (YAMAUCHI et al.[11]), which were obtained from local slaughterhouses during the period from May 1957 to July 1964. Sixty-one pregnant uteri containing a fetus varying from 5 cm to 79 cm in Crown-Rump (C.R.) length were used. Because of no information was available on all of them with respect to the date of breeding, materials were arranged according to the C.R. length of the fetus (Table 1). The whole uterus from which the fetus was removed, has been preserved in 10% formalin. Tissue blocks were obtained

NII-Electronic Library Service

Osaka Prefecture University

from the intercaruncular region of both pregnant and contralateral horns at the middle of free margin (anti-mesometrial margin). After washing and dehydration, tissue blocks were embedded in paraffin. Serial sections with the thickness of 10 micra were cut and were stained, exclusively, with Delafield's hematoxylin and eosin.

For the purpose to clarify the change of uterine glands during pregnancy, measurements on size of the gland and height of an epithelium were undertaken. In this paper, uterine glands were classified into two groups according to their location. Superficial glands refer to those locating in *s. compactum* (excluding a neck segment of the gland) and *s.spongiosum.* Meanwhile, basal glands refer to those locating in *s.basale.* Measurements were, thus, undertaken on four different regions in each material. An outer diameter of the gland was measured with an aid of ocular micrometer. In each material, forty glands having a round outline were measured, then the mean diameter was obtained. In a same way as described above, the mean height of the glandular epithelium was obtained after forty measurements on epithelial cells in each material. Apart from this, materials were grouped into groups of every 5 cm in it's C.R. length as shown in Table 3. Mean diameter of the gland as well as mean height of the glandular epithelium were also obtained.

In a present study, the quantity of secretions in a gland lumen was represented according to the following standards:

−	No secretion is found at all in all lumens.
±	Trace of secretion is present in a few lumens.
+	Small to moderate quantity of secretion is present in about a half of lumens.
++	Small to moderate quantity of secretion is present in more than half of lumens.
+++	Large quantity of secretion is present in most lumens.

Observations

1. Size and shape of uterine glands.

An appreciable and gradual increase in diameter of uterine glands was noted in superficial as well as basal glands in both pregnant and contralateral horns. The smallest diameter was found in an uterus containing a fetus of 5 cm in C.R. length. In a meantime, the largest one was found in uteri containing a fetus of 74 cm and 76 cm in C.R. length, respectively. The result seems to indicate a tendency that the gland diameter increases with an advancement of the pregnancy (Table 1, Figs. 1 and 2).

The data tabulated in Table 2 show the ratio of increment in gland diameter, i.e., 2.4 for superficial gland in pregnant horn, 3.0 for superficial gland in a contralateral horn, 4.1 for basal gland in a pregnant horn and 3.8 for basal gland in a contralateral horn, respectively. The result seems to indicate that the tendency of increases is more pronounced in basal glands than in superficial glands. In a pregnant horn of the uteri containing a fetus larger than 70 cm in C.R. length, the lamina propria becomes to be flattened out. The glands are therefore, found distributed only in a few layers as shown in Fig. 10. The identification of superficial gland or basal gland in these horns becomes very difficult.

Table 3 shows a mean diameter of glands when the materials were grouped by every 5 cm in C.R. length and the result is also illustrated in Fig. 3. In both horns, superficial glands seem to be larger than basal glands with a minor exception. The

NII-Electronic Library Service

Osaka Prefecture University

Table 1. Tabular view of the materials included in the study. Results of a measurment on the uterine gland and an evaluation on the glandular secretions are also presented.

No.	Crown Rump length of fetus in cm	Pregnant horn	Diameter of the uterine gland in μ				Height of the gland epithelium in μ				Quantity of the luminal secretions			
			Pregnant horn		Contralateral horn		Pregnant horn		Contralateral horn		Pregnant horn		Contralateral horn	
			Superficial	Basal	Superficial	Basal	Superficial	Basal	Superficial	Basal	Superficial	Basal	Superficial	Basal
1 A750	5	R	104	54	91	54	23.8	12.5	26.2	12.9	±	−	±	−
2 B149	5	L	56	33	41	36	18.1	13.1	24.7	10.0	−	−	−	−
3 A772	7	L	65	45	79	47	18.6	11.3	22.6	11.2	±	−	±	−
4 A756	9	L	108	77	64	38	24.5	15.7	21.1	15.0	±	±	−	±
5 A790	9	R	72	47	72	53	22.6	16.4	18.7	11.2	−	±	±	−
6 A761	9	R	74	48	69	45	17.1	12.4	18.3	9.8	+	−	+	−
7 A745	10	R	71	60	91	63	19.7	15.5	16.3	14.4	+	±	±	−
8 B174	10	R	93	77	57	41	17.8	14.1	17.8	11.2	+	+	−	−
9 B144	10	L	70	39	73	52	17.5	10.7	18.3	8.6	+	−	+	−
10 A741	12	R	76	55	78	58	18.5	14.2	16.7	14.3	+	±	+	+
11 A770	13	L	74	54	60	39	16.8	11.5	12.4	9.6	+	+	++	−
12 A838	13	L	62	42	56	38	18.8	9.4	16.7	14.1	±	−	+	−
13 A749	14	R	89	78	79	63	17.9	14.3	17.2	13.1	±	±	±	−
14 A748	15	R	83	81	53	50	19.2	12.3	16.9	11.2	±	+	−	−
15 A804	15	L	101	77	101	59	24.6	17.4	26.8	18.4	+	+	+	−
16 A794	15	R	83	62	64	89	17.2	14.9	16.3	15.4	+	+	+	±
17 A792	15	R	78	60	70	51	18.1	12.1	17.7	9.4	+	±	+	−
18 A786	16	L	129	63	114	51	20.4	11.9	21.3	12.2	+	−	+	−
19 B137	16	R	81	65	67	48	16.5	14.6	18.6	13.3	+	++	++	+
20 B147	17	L	74	51	66	49	12.2	11.0	15.9	11.1	+	+	±	+
21 B138	17	L	74	51	65	47	20.5	13.7	19.7	11.9	+	±	+	+
22 A793	17	L	78	69	70	49	19.8	14.4	19.8	14.4	++	++	++	±
23 B181	17	R	111	69	94	64	16.9	11.0	15.8	12.2	+	+	+	+
24 A812	18	R	93	63	80	82	21.5	10.8	21.0	15.7	+	−	++	++
25 B135	18	R	75	60	68	60	17.4	13.8	19.0	15.5	++	++	±	±
26 A755	22	R	77	70	80	67	20.5	16.7	24.2	15.9	+	+	±	+
27 A747	22	L	124	115	105	85	22.4	15.1	21.0	13.3	+	+	+	+
28 B152	22	L	106	83	71	58	19.8	17.7	19.3	14.4	++	++	++	++
29 A739	23	R	101	72	108	63	20.4	14.9	22.3	13.5	++	±	++	+
30 A738	23	L	116	98	97	93	18.2	16.1	20.2	10.7	+	+	+	+
31 A789	23	R	90	89	88	86	18.4	16.4	21.0	15.8	++	++	+	+
32 A760	25	L	117	111	97	86	22.5	15.5	21.1	13.5	+	+	++	+
33 A757	26	R	80	86	106	85	21.5	12.7	23.0	15.2	±	+	+	+
34 A873	26	R	114	99	83	63	18.5	13.7	16.3	12.1	+	+	+	±
35 A800	26	R	118	98	80	69	12.5	10.4	19.0	13.5	+	+	++	+
36 A742	28	L	111	67	99	76	24.4	12.8	21.5	12.2	+	+	+	+
37 A779	28	L	73	70	100	64	15.9	14.1	19.0	15.1	++	++	+	++
38 A798	28	L	92	87	94	72	13.9	13.3	17.0	7.7	++	++	+	+
39 A728	30	L	105	104	87	82	19.0	13.7	16.9	11.8	++	++	++	++
40 B154	31	R	76	71	68	69	21.4	17.9	21.1	17.0	++	+	+	+
41 A775	32	R	110	82	83	77	15.6	12.8	13.3	11.1	+	+	+	+
42 A765	33	L	113	131	87	96	22.1	11.3	18.2	9.9	+	++	+	++
43 A744	33	R	77	73	64	54	16.9	16.0	10.9	9.5	+	+	±	±
44 A731	35	R	124	101	117	92	20.5	17.6	18.4	15.6	+	+	+	+
45 B166	39	R	162	126	139	123	24.6	16.6	21.3	15.4	+	+++	+	+++
46 A751	45	R	82	77	79	62	17.2	13.7	12.7	10.1	+	+	+	+
47 B180	45	R	102	90	84	80	13.7	12.3	15.0	13.8	+	+	+++	++
48 A734	46	R	120	84	102	67	19.1	15.7	23.9	14.3	+	+	+	++
49 B151	48	R	128	114	77	69	31.9	31.7	20.7	17.8	++	++	++	++
50 B150	50	L	108	116	108	97	22.3	18.7	15.6	15.4	±	+	+	+
51 A732	51	R	95	96	74	64	15.3	13.7	18.8	9.8	+	+	+	+
52 B158	53	L	118	117	76	76	25.6	28.1	22.1	20.3	+	+	++	++
53 B156	55	R	121	113	115	95	20.7	13.9	18.8	15.6	+	+	+++	++
54 A729	55	R	95	114	89	91	22.1	17.3	20.9	17.6	+	++	++	+++
55 B153	55	L	96	97	73	57	22.0	21.1	16.3	16.3	+	+	+	++
56 B170	60	R	122	102	105	92	17.5	16.3	16.7	13.3	++	+	++	++
57 B177	70	L		128	109	93		20.5	23.9	17.3		++	+	+
58 B163	74	L		135	126	117		18.9	17.8	18.4		+	+++	+++
59 B164	74	R		124	117	94		17.0	16.4	17.5		+	++	+
60 B165	76	L		110	141	138		22.2	19.2	18.4		++	++	++
61 B159	79	L		117	121	120		22.7	21.7	23.3		++	++	++

NII-Electronic Library Service

Osaka Prefecture University

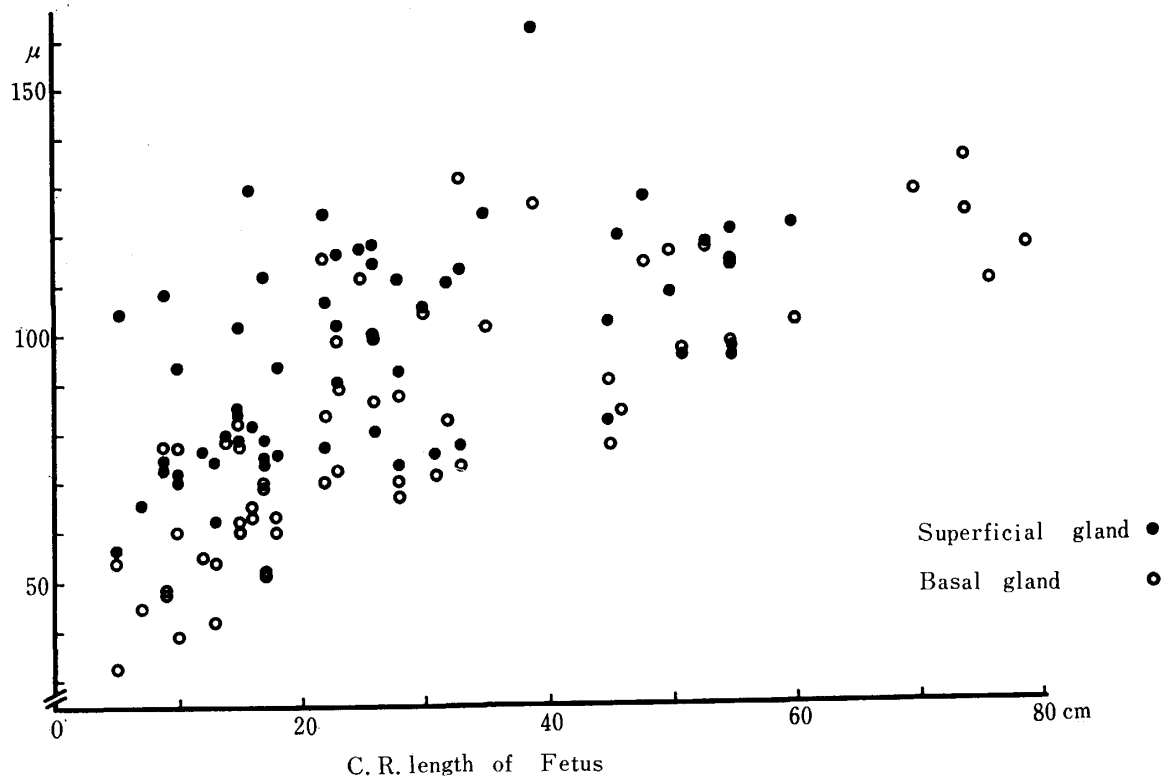

Fig. 1. Diameters of uterine glands in a pregnant horn with an advancement of gestation.

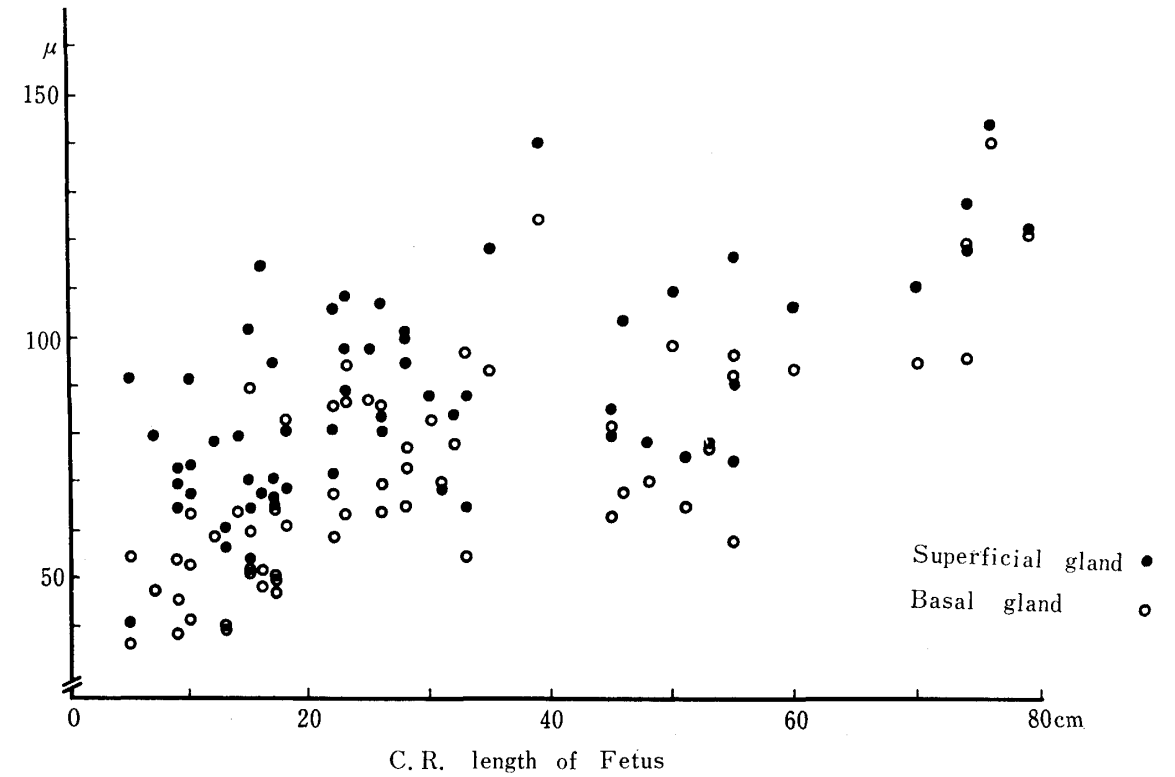

Fig. 2. Diameters of uterine glands in a contralateral horn with an advancement of gestation.

NII-Electronic Library Service

Osaka Prefecture University

Table 2. Comparison of minimum and maximum diameters of the gland. The ratio of increase is also presented.

		Minimum (μ)	Maximum (μ)	Ratio
Pregnant horn	Superficial gland	56 (No. 2, C.R.L. 5cm)	135 (No. 58, C.R.L. 74cm)	1 : 2.4
	Basal gland	33 (No. 2, C.R.L. 5cm)	135 (No. 58, C.R.L. 74cm)	1 : 4.1
Contra-lateral horn	Superficial gland	41 (No. 2, C.R.L. 5cm)	141 (No. 60, C.R.L. 76cm)	1 : 3.0
	Basal gland	36 (No. 2, C.R.L. 5cm)	138 (No. 60, C.R.L. 76cm)	1 : 3.8

diameter of superficial gland as well as basal gland in the pregnant horn are invariably larger than those in the contralateral horn, respectively. All four components illustrated in Fig. 3 seem to show three phases, respectively. The first phase corresponds to the stage in which a C.R. length of the fetus is ranged from 5 cm up to 25 cm; the middle phase to the stage ranging from 25 cm up to 60 cm, and the last phase to the stage ranging from 60 cm up to 79 cm. In the first phase, basal glands in both horns increase in diameter remarkably, then in a middle phase that tendency becomes less distinct than before, and in the last phase, the uterine glands in the contralateral horn increase in diameter remarkably attaining nearly those in the pregnant horn.

The uterine gland, in a histological section, is predominantly round otherwise ellipsoid. In addition, various cross-sections of the gland were frequently encountered,

Table 3. Diameter of the uterine gland and height of the gland epithelium. Materials are being grouped into groups of every 5 cm in C. R. length.

Crown-Rump length of fetus in cm	Number of Animals	Diameter of the uterine gland in μ				Height of the gland epithelium in μ			
		Pregnant horn		Contralateral horn		Pregnant horn		Contralateral horn	
		Superficial	Basal	Superficial	Basal	Superficial	Basal	Superficial	Basal
5- 9	6	80	51	69	46	20.8	13.5	21.9	11.7
10-14	7	76	58	71	51	18.1	12.8	16.5	12.2
15-19	12	88	64	76	58	18.7	13.2	19.1	13.4
20-24	6	102	88	92	75	20.0	16.2	21.3	13.9
25-29	7	101	88	94	74	18.5	13.2	19.6	12.8
30-34	5	96	92	78	76	19.0	14.3	16.2	11.9
35-39	1	124	101	117	92	20.5	17.6	18.4	15.6
40-44	0								
45-49	4	108	91	86	70	20.4	18.4	18.1	14.0
50-54	3	107	110	86	79	21.1	20.2	18.8	15.2
55-59	3	104	108	92	81	21.6	17.4	18.7	16.5
60-64	1	122	102	105	92	17.5	16.3	16.7	13.3
65-69	0								
70-74	3		129	117	101		18.8	19.4	17.7
75-79	2		114	130	129		22.5	20.5	20.9

NII-Electronic Library Service

Osaka Prefecture University

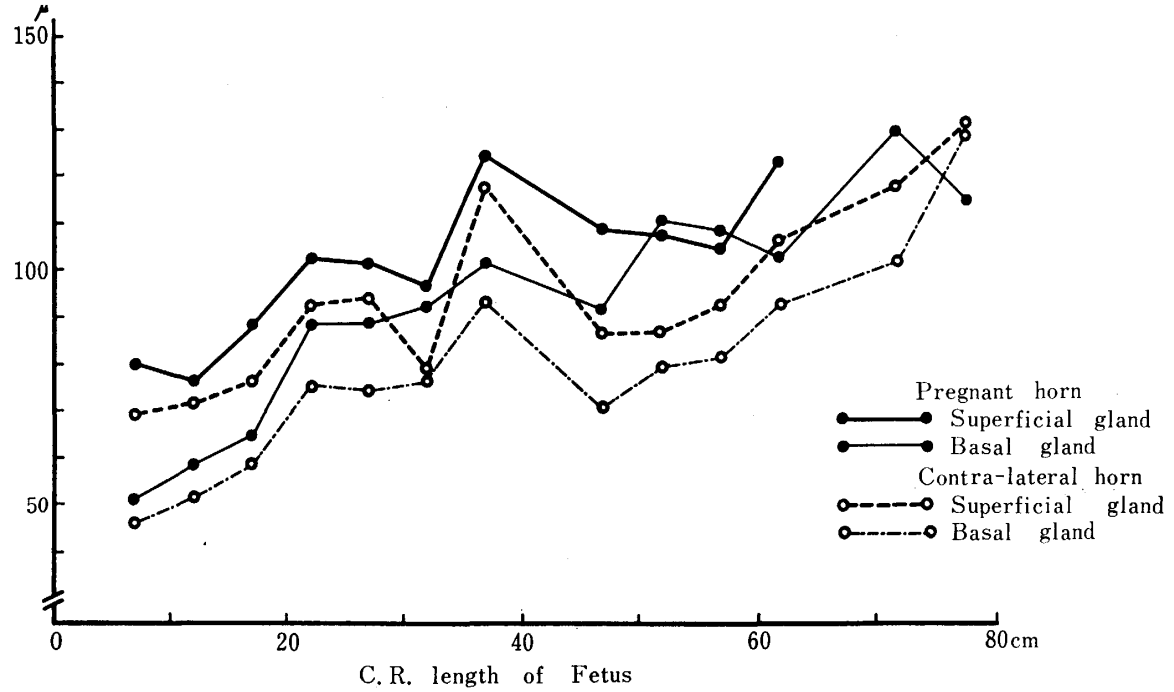

Fig. 3. Change in diameter of uterine glands with an advancement of gestation. Data presented in Table 3 were introduced.

which seems to show a spiral course of the gland tubule. Glands in uteri especially in a late stage of gestation mostly showed irregular and complex shapes. A difference in shape of uterine glands between two horns as well as between superficial and basal glands was discernible up to the stage of pregnancy when a fetus attains 50 cm in it's C.R. length (Figs. 7 and 8). Branching or budding of the gland was not noted during this stage (Compare Figs. 5 and 6 with Fig. 9).

Owing to the growth of fetus, the uterine wall especially of the pregnant horn becomes progressively thinner. The round glands decrease in number and most glands become irregular in shape as seen in Fig. 10. Though an appreciable increase in size of the contralateral horn was noted, uterine wall seemed to be less affected than the pregnant horn. In a contralateral horn, branching or budding of the gland was frequently noted (Figs. 9 and 11). The uterine glands in both horns at this stage seemed to be distended and some of them showed a cyst-like character.

2. Findings on the glandular epithelium.

1) Height of epithelial cells. The result is shown in Table 1. With respect to the height of epithelium, interesting changes were noted between superficial and basal glands in both pregnant and contralateral horns, respectively. From the data presented in Table 4, it will be noted that the least gland epithelia were present not restricted in uteri containing the smallest fetus and vice versa. As described in a preceding section, the materials were grouped into groups of every 5 cm in C.R. length. A mean of each group is shown in Table 3 and the result is illustrated in Fig. 4. For the purpose of further consideration, tallest and lowest height of the epithelium in four different region in an uterus are shown in Table 5.

In a superficial gland in both pregnant and contralateral horns, the difference between the tallest and the lowest epithelia was 5.0 micra and 4.7 micra, respectively. Meanwhile, in a basal gland, it was 9.7 micra and 9.2 micra, respectively. As shown in Table 3 and Fig. 4, epithelial cells of the superficial gland in both pregnant and contralateral horns

NII-Electronic Library Service

Osaka Prefecture University

Table 4. Comparison of minimum and maximum heights of the gland epithelium. The ratio of increase is also presented.

		Minimum (μ)	Maximum (μ)	Ratio
Pregnant horn	Superficial gland	12.2 (No. 20, C.R.L. 17cm)	31.9 (No. 49, C.R.L. 48cm)	1 : 2.6
	Basal gland	9.4 (No. 12, C.R.L. 13cm)	31.7 (No. 49, C.R.L. 48cm)	1 : 3.4
Contra-lateral horn	Superficial gland	12.4 (No, 11, C.R.L. 13cm)	26.8 (No. 15, C.R.L. 15cm)	1 : 2.2
	Basal gland	7.7 (No. 38, C.R.L. 28cm)	23.3 (No. 61, C.R.L. 79cm)	1 : 3.0

Table 5. Comparison of minimum and maximum heights of the gland epithelium. Data were introduced from Table 3. The difference between two extremities is also presented.

		Maximum (μ)	Minimum (μ)	Difference
Pregnant horn	Superficial gland	22.5 (75cm - 79cm)	17.5 (60cm - 64cm)	5.0 μ
	Basal gland	22.5 (75cm - 79cm)	12.8 (10cm - 14cm)	9.7 μ
Contra-lateral horn	Superficial gland	21.9 (5cm -9 cm)	16.2 (30cm - 34cm)	4.7 μ
	Basal gland	20.9 (75cm - 79cm)	11.7 (5cm - 9cm)	9.2 μ

varied within a range of about 5 micra throughout a gestation period. Accordingly, no substantial increase in height of the epithelium seems to occur in a superficial gland. On the contrary, the basal gland showed a remarkable increase with an advancement of gestation.

From the data recorded in this study, it will be concluded that the epithelium of superficial glands is invariably taller than that of basal glands. No conclusive difference in respect to the height of epithelium was shown between superficial glands in pregnant and contralateral horns. Meanwhile, when basal glands were compared, the epithelium in a pregnant horn seemed to be slightly higher than that in a contralateral horn in most stages, although the difference in each stage was not remarkable.

2) Characteristics of epithelial cells. As a rule, the epithelium of superficial glands is single, columnar throughout pregnancy (Fig. 12). Some glands consisted of low columnar or cuboidal cells were also present particularly in uteri containing a fetus larger than 30 cm in C.R. length (Fig. 20). The epithelium of basal glands in an early stage, meanwhile, consisted of single, columnar or cuboidal cells (Figs. 13 and 23). With the advancing gestation, epithelial cells gradually change into columnar cells. There were commonly present some glands which show a pseudostratified type. Though the cross-section of convoluting or spiral segment of the gland tubule seems to be a stratified epithelium, a careful examination on serial sections revealed that basically the gland consists of a single epithelium.

NII-Electronic Library Service

Osaka Prefecture University

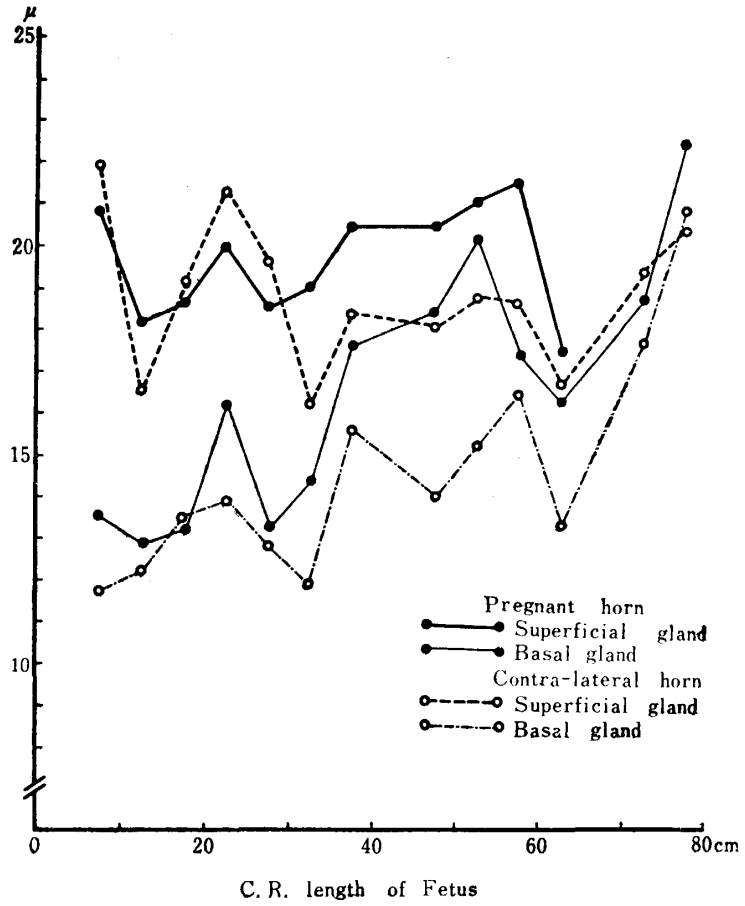

Fig. 4. Change in height of gland epithelia with an advancement of gestation. Data presented in Table 3 were introduced.

A destruction of epithelial cells was frequently found in superficial glands in an early stage, being more distinct in glands nearer the surface. As shown in Figs. 29 and 30, an erosion of the epithelium seems to be preceded by an appearance of inter- or intracellular vacuoles and was observed equally in sections obtained from both pregnant and contralateral horns, although the erosion was found restricted to limited glands. In most uteri containing a fetus ranging from 5 cm to 25 cm in C.R. length, superficial glands in both horns showed a moderate erosion of epithelium and in a few uteri in a later stage than above, a similar erosion was noted. The erosion of the epithelium was found restricted to superficial glands only and was never found in basal glands in both pregnant and contralateral horns.

In an early stage of pregnancy, epithelial cells were predominantly granular, although the quantity of granules varied widely between cells as well as materials (Figs. 15 and 16). The distal margin of the epithelium showed various features as shown in Figs. 15, 18 and 27 and a brush border was commonly found in many cases (Figs. 12 and 16).

Superficial gland in a pregnant horn. In an early stage of pregnancy, only a small quantity of cytoplasmic granules was noted. With an advancing gestation, there appeared a cyclic change in an epithelium. Cytoplasmic processes were noted in glands in uteri containing a fetus ranging from 5 cm to 30 cm in C.R. length (Fig. 15). Intracellular materials seemed to be discharged into the gland lumen from the distal margin. Such a secretory activity seems to commence at about the stage when a fetus

NII-Electronic Library Service

Osaka Prefecture University

attains 10 cm in C.R. length, thereafter it continues throughout the gestation period and seems rather intense in a late stage (Fig. 26).

Superficial gland in a contralateral horn. Similarly as above, cytoplamic processes were noted mainly in glands in uteri containing a fetus ranging from 5 cm to 25 cm in C.R. length (Fig. 17). Epithelial cells were mainly granular in uteri containing a fetus less than 30 cm in C.R. length (Figs. 16 and 17). The epithelial secretion seems to commence somewhat later than in a pregnant horn, being most pronounced in uteri containing a fetus larger than 50 cm in C.R. length (Fig. 18).

Basal gland in a pregnant horn. In an early stage, the epithelium was consisted exclusively of cuboidal cells. The cytoplasmic area being mostly occupied by the nucleus, was either agranular or weak granular. No characteristic feature but only a faint brush border was identified (Fig. 13). Above described feature were commonly found in uteri containing a fetus less than 15 cm in C.R. length. With an advancing gestation, there appeared a cytoplasmic change concomitantly with the change in shape of the cell. The infranuclear region of cytoplasm becomes to contain dust-like materials, meanwhile, the supranuclear region becomes weak granular. A secretory activity appeared at about the stage when the fetus attains 30 cm in C.R. length.

Basal gland in a contralateral horn. Similarly as above, only a small area of the cytoplasm could be identified in an early stage (Fig. 14). During this stage, the cytoplasm was exclusively agranular. Secretory signs of the epithelium appeared gradually, being more pronounced in uteri containing a fetus larger than 45 cm in C.R. length (Figs. 19 and 25).

3) Nuclei. The nucleus seems to vary its shape according to the change in shape of the cell. Most of them were round or ellipsoid and located basally. Apart from this, spindle-shaped and distally located nuclei were also found. In an early stage, enlargement or swelling of the nucleus was noted in both pregnant and contralateral horns, and some swollen nuclei were occasionally found in a gland lumen (Fig. 29). In a meanwhile, pycnotic nuclei were found in glands in an uterus in a late stage of gestation and occasionally some were also found in a gland lumen (Figs. 20 and 22).

In a pregnant horn, mitotic figures of epithelial cells were equally found in both superficial and basal glands in most uteri containing a fetus larger than 23 cm in C.R. length (Fig. 28). Almost the same was the case for superficial glands in a contralateral horn, the mitotic figures were found only in a few cases of uteri containing a fetus ranging from 40 to 60 cm in C.R. length.

4) Intraepithelial wandering cells. The cells referred here are mostly small, round and deeply stained cells with a dark nucleus. These characteristics would suggest that these wandering cells may be lymphocytes. They locate mainly intercellularly and basally. In a pregnant horn of uteri containing a fetus larger than 10 cm in C.R. length, an intraepithelial infiltration was invariably noted, being far pronounced in materials containing a fetus larger than 50 cm in C.R. length (Fig. 26). In a contralateral horn, lymphocyte were commonly found in an epithelium of materials having a fetus larger than 15 cm in C.R. length. No distinct difference in distribution of lymphocytes was noted between superficial and basal glands. More lymphocytes were seemed to present in materials in a late stage of gestation than in an early stage.

3. Glandular secretions

In a strict sence, the luminal mass mainly derived from the desquamation of epithelium, which is commonly found in materials in an early stage of gestation, should not be regarded as glandular secretions. For the purpose of convenince, it will be described here with the true secretions. Various features of the mass disclosed in a present study are shown in Figs. 21, 24 and 29. Cell nuclei derived from the desqua-

NII-Electronic Library Service

Osaka Prefecture University

mation of epithelium and lymphocytes were frequently found in a luminal mass. The quantity of secretions varied in relation to the change of the secretory activity of the epithelium and a evaluation on a quantity of secretions is tabulated in Table 1.

In a superficial gland of the pregnant horn, a trace of secretion was noted as early as in a material which contain a fetus of 5 cm in C.R. length. Thereafter, moderate amount of secretion was invariably noted up to the stage when the fetus attains 10 cm in C.R. lengh. In a basal gland, on the other hand, moderate amount of secretion was first noted in a material which contains a fetus of about 15 cm in C.R. length. From this stage on, no striking difference in respect to the quantity of secretion was noted between superficial and basal glands.

Similar tendency as described above was also noted in uterine glands in a contralateral horn. In a superficial gland, a quantity of secretions attained moderate amount by the stage when a fetus attains 10 cm in C.R. length. In a basal gland, meanwhile, a moderate amount of secretions was first noted at the stage when a fetus attained 16 cm in C.R. length. Thereafter, no striking difference in respect to the quantity of secretions was noted between superficial and basal glands.

Discussion

In open cows, the uterine gland has been described to be a branched, tubular gland.[12,13,14,15,16] Cole[12] further stated that glands branch very often in the zone just below the surface. In addition, the gland has also been considered to be spiral or turtuous by above authors. Nevertheless, the definitive evidence of the branching of uterine glands has not been shown. Recently, Vogel[16] succeeded to show the branching of the gland by means of the maceration of the total gland. In a present study, the histological evidence for the branching was not obtained except a few cases in a late stage of gestation. Because of intense spirality or coiling, more cross-sections of the gland were present in a deeper layer of an endometrium in a given histological preparation.

Weber et al.[13] divided the gland into three segments; i.e., neck, middle and basal regions. Apart from this, the gland has been variously divided by many authors up to the date.[5,9,12,17,18] Not only different morphology but also different activity of the epithelium in relation to different segments of the gland have been reported. In a present study, distinct differences in respect to diameter of the gland and height of epithelial cells were revealed between superficial and basal glands. In addition, the neck segment was confirmed to be different from other two segments. It seems reasonable, therefore, to divide the uterine gland into three segments just described above.

Earlier studies on materials during a normal estrous cycle have shown the changing morphology within a cycle. In a luteal phase of the cycle, the degree of coiling was shown to be increased.[5,12,15,19,20,21] According to Asdell,[22] the gland begins to grow a few days after the onset of estrous and attains a maximum development at about 12-day postestrous. Vogel[16] disclosed the difference in morphology of uterine glands between various groups of cows (age, cyclic phase, degree of parity). According to him, the morphology of the uterine gland also depends on a distance from the caruncle. In addition to the side pocket which has frequently been referred in a literature, he disclosed acini in a fully developed uterine gland.

A secretory activity of the glandular epithelium has been also shown to be increased by progesterone,[12,17,18,25,26] and concomitantly, the gland lumen becomes to be filled with secretory materials.[15,19,20] Cyclic changes have been stated to appear

NII-Electronic Library Service

Osaka Prefecture University

most markedly in the deep glands by HAMMOND.[5] In this connection, he stated that the cycle is essentially a pregnancy on a small scale.

It is generally accepted that, in an early stage of pregnancy, the uterine epithelium always persisted around the openings of glands. The glandular secretion has been considered, in preventing the close adherence of the trophoblast, shields the glandular epithelium from the phagocytic action of the trophoblast.[1,2,3,4,10,23,24] A slight erosion of the epithelium confined to the superficial gland was disclosed in both pregnant and contralateral horns of the uterus containing a fetus up to 28 cm in C.R. length. From this finding, some lytic substance derived from the trophoblast seems to infiltrate into uterine glands.

Similarly as surface epithelial cells, glandular epithelial cells also contain lipid, glycogen, periodic acid-Schiff positive substances and alkaline phosphatase. Meanwhile, lipid and glycogen were found restricted to the neck segment of the gland or superficial and occasionally also intermediate glands.[5,9,17,18] It is well known that the so-called uterine milk is essentially important for the developing fetus and fetal membranes in an early stage of pregnancy. In this connection, AMOROSO[4] stated that uterine glands expand greatly and actively secrete at the preimplantation stage. According to CHANG[27] the implantation in the bovine is very late but the uterine milk is in abundance in the lumen of the uterus from the time when the blastocyst is at an early stage up till about 24 days, or a little later in some cases, while HAMMOND[5] stated that during gestation, uterine glands secrete the uterine milk which nourishes the fetus both before and after its attachment to the uterus.

It is also well known that the uterine glands of mammals dilate and hypertrophy during pregnancy, nevertheless, the extent and character of this growth have not been explained enough yet as far as authors are aware. In a present study, diameters of superficial gland as well as basal gland in both pregnant and contralateral horns were shown to increase with advancing pregnancy. It seems interesting to note that diameters of superficial and basal gland in a pregnant horn are larger, in most cases, than those in the contralateral horn, respectively. Owing to the extreme expansion of the uterus in a late stage of pregnancy, glands became very irregular in shape. Nonetheless, the glands were seemed to increase in diameter steadily till the term and the gland frequently exceeded 100 micra in diameter in a late stage.

In this connection, HAMMOND[5] stated that basal glands begin to grow later than superficial glands and both glands continue to increase in diameter as well as activity throughout the gestation period. Meanwhile, in a sheep, WIMSATT[10] stated that all segments of the gland increase in diameter as gestation progresses, but the more distal segment do so at a slightly greater rate than the neck portions so that at term the distal segments are as wide as, and sometimes wider than, the proximal portion. On the other hand, according to WEETH and HERMAN,[9] the gland continues to enlarge during gestation and its luminal diameter attains 90 micra by 142 days but there appears to be very little further increase in luminal size of the glands during the latter half of gestation.

Early in gestation, superficial gland and basal gland were easily discernible each other according to its shape and size. With an advancing gestation, basal glands grow more rapidly than superficial glands therefore in a late stage of pregnacy, both glands became approximately the same size as already suggested by HAMMOND[5] and WIMSATT.[10] The glands in an early stage were, as in an uterus of non-pregnant cow, cylindrical or round in cross-section. HAMMOND[5] stated that from the 3rd month of pregnancy onward, the glands are no longer circular in outline, because of the marked lateral pressure. According to WIMSATT,[10] the glands in a sheep uterus during the

NII-Electronic Library Service

Osaka Prefecture University

second half of pregnancy, become more compressed within the thinning endometrium with the result that the glands are now flattened ellipse in cross-section. In a present study, similar findings were confirmed in most cases in a late stage of pregnancy.

According to HATCH,[2] the glandular epithelium remains constant in size and type throughout pregnancy and the average height of the glandular epithelium deep in a submucosa is 23 micra. Meanwhile, WEETH and HERMAN[9] stated that during pregnancy, epithelial cells are low columnar and vary little from 15 micra in height and the epithelial height in the gland necks is about 5 micra taller than in the terminals. In this regard, the present findings seem to be valuable in evaluating an activity of different segments of the gland. Epithelial cells of superficial glands in both pregnant and contralateral horns showed no distinct variation in height during pregnancy. On the other hand, those of the basal glands in both uterine horns showed a steady but remarkable increase in height with an advancement of pregnancy with the result of approximately the same epithelial height as that of the superficial gland.

Secretory activity was found to increase till the end of pregnancy. Secretory cells appeared first in a superficial gland in a pregnant horn, then appeared in that in a contralateral horn, basal gland in a pregnant horn and that in a contralateral horn, in orderly fashion. Previously, HAMMOND[5] suggested that there was present a secretory activity in a superficial gland in 2nd month of pregnancy, and that activity may be found in both superficial and basal glands from the 3rd month onward. On the other hand, FOLEY and REECE[8] suggested the secretory actitvity of the glands in upper zones of the endometrium in an early stage (between 25 and 28 days of pregnancy), thereafter the secretory activity extends to the deeper-lying glands. The findings relating to the regional difference in commencement of the secretion of uterine glands may suggest that the ingestion of histotrophe by the chorionic trophoblast in a contralateral horn begins later than in a pregnant horn.

In a late stage of pregnancy, uterine glands having an irregular, cyst-like outline were frequently found especially in a contralateral horn. Cystic glands in a bovine uterus have been reported previously,[28,29,30] and the estrogenic influence has been considered to be the principal factor as already suggested by NELSON.[31] The cyst-like glands disclosed in this study seem to be different from above cystic glands not only in its distribution but also in its morphology.

In a pregnant horn, proliferated epithelial cells would be promptly mobilized to hypertrophy and extension of the gland. In a contralateral horn, meanwhile, a distension of the horn is not so enormous as that of the pregnant horn, hence the glands extend presumably far less in length than in pregnant horn. Thereby, the surplus cells have probably been resulted in forming a cyst-like protrusion. In this connection, WIMSATT[10] stated that, in a sheep uterus, one characteristic of the gland tubules in later stage is the formation of short blind side pockets which further increase the glandular surface. According to him, the uterine glands during pregnancy may increase their length by four times and their girth by ten.

Periglandular stroma has been described to be different from the general endometrium in its constitution, being rich in histochemical substances and white blood cells.[8,9,17] According to AMOROSO,[4] lymphocytes increase in number at a preimplantation stage and migrate toward the uterine lumen. In addition to lymphocytes, other blood cells have been considered to be a substantial component of the uterine milk. NELLOR and BROWN[32] stated that, in a genital tissue, the progestational agent induces or stimulates the plasma cell production from the fibroblast-like cell, and these white blood cells easily penetrate into the epithelium. In a present study, intraepithelial

NII-Electronic Library Service

Osaka Prefecture University

lymphocytes were noted very often in many cases. Some of them were also noted in a gland lumen.

Summary and Conclusions

Histological study on the uterine gland in a cow was carried on a total of sixty-one pregnant uteri which contain a fetus ranging from 5 cm to 79 cm in C.R. length. Particular attentions were paid to the changing morphology which relates to the advancing gestation. The results obtained are as follows.

1. In an early stage of pregnancy (up to the stage when a fetus attains 9 cm in C.R. length), the superficial gland in pregnant and contralateral horns is larger than the basal gland, respectively. The diameter of the former is 80 micra and 69 micra, and that of the latter is 51 micra and 46 micra, respectively. The result also shows that both superficial and basal glands in a pregnant horn are larger than those in a contralateral horn, respectively.

Both glands in pregnant as well as contralateral horns increase in diameter with an advancement of pregnancy, in which ratios of increment in diameter of basal glands are larger than those of superficial glands in both horns. Thus, in a late stage of pregnancy, when the fetus is 70 cm-74 cm and 75 cm-79 cm in C.R. length, all glands in four different regions in an uterus show about 130 micra in diameter.

2. In an early stage of pregnancy, glands are predominantly round in a histological section and a greater number of glands were present in a given field than in a later stage. In both horns, cross-sections of the basal gland are larger in number than those of the superficial gland. Cross-sections of glands per field decrease in number with an advancement of pregnancy. In a late stage of pregnancy, glands of irregular shape or cyst-like glands appear gradually.

Changes in shape of the gland and reduction in number of the gland were more pronounced in a pregnant horn. On the contrary, branched glands appeard in large number in a contralateral horn. The difference in distribution as well as morphology of uterine glands between pregnant and contralateral horn in a late stage of pregnancy is probably due to the difference in distention of an uterine wall between two horns. In contralateral horn proliferated epithelial cells would be mobilized in forming a cyst-like gland.

3. A slight denudation of the epithelium occurs in superficial glands in both horns of uteri containing a fetus less than 28 cm in C.R. length. The denudation probably occurs due to the histolytic function by trophoblast cells rather than due to the mechanical friction by the trophoblast.

4. The epithelia of superficial glands in both horns maintain an almost constant height regardless of an advancement of pregnancy. The data obtained show a range of 17.5 micra to 22.5 micra in a pregnant horn, and 16.2 micra to 21.9 micra in a contralateral horn, respectively. In a basal gland in an early stage, on the contrary, the epithelium is 12.8 micra in a pregnant horn and 11.7 micra in a contralateral horn, respectively. The epithelia of basal glands show, though gradual, a distinct increase in height with an advancement of pregnancy. Thus, in a late stage of pregnancy, an epithelium of the basal gland shows 22.5 micra in a pregnant horn and 20.9 micra in a contralateral horn, respectively. From this data, it may be concluded that in a late stage of pregnancy, the epithelium of the basal gland attains almost the same height as that of the superficaial gland.

5. In both superficial and basal glands, the epithelium is, as a rule, a simple

NII-Electronic Library Service

Osaka Prefecture University

epithelium. In a superficial gland the epithelium is lined by columnar cells throughout the gestation stage. Meanwhile, in a basal gland it is lined by cuboidal cells in an early stage, which changes into columnar cells with an advancement of gestation. A cytoplasm of the epithelial cell in an early stage, is generally divided into two regions, i.e., a supranuclear region being faint granular and a subnuclear region which contains a mass of thread-like material. With an advancement of gestation, the granularity of the cytoplasm becomes more intense, beside the secretory activity of the epithelium in apocrine type increases toward the late stage.

Changes of epithelial cells mentioned above appear first in a superficial gland in a pregnant horn. Thereafter they successively appear in a superficial gland in a contralateral horn, basal gland in a pregnant horn, then in a basal gland in a contralateral horn, in this order. Changes in character of epithelial cells are intimately correlated with the quantity of the luminal secretions.

6. Migrating cells found intraepithelially as well as in a periglandular stroma seem to be lymphocytes which, though absent in materials in an early stage, increase in number equally in both superficial and basal glands in both two horns with an advancement of gestation.

7. Nuclei of epithelial cells are mostly round or oval in shape and locate usually in a proximal one-third of the cell. A few nuclei of the epithelium in superficial glands in both horns show a distinct enlargement or swelling in an early stage. Meanwhile, during pregnancy, in both superficial and basal glands in two horns, pycnosis of the cell nucleus appears frequently and some pycnotic nuclei were also found in a gland lumen.

8. The secretions were noted first in a lumen of the superficial gland in a pregnant horn in an early stage. Thereafter, the secretions were successively noted in a superficial gland in a contralateral horn, basal gland in a pregnant horn, then that in a contralateral horn. Luminal secretions in all four regions seem to increase in quantity with an advancement of gestation. In a later stage of pregnancy, the quantity of secretions in both glands in a contralateral horn seems to be larger than that in a pregnant horn.

References

1. Björkman, N. Acta Morphol. Neerlando-Scandinavica, **1**, 1-10, 1956.
2. Hatch, R.D. Amer. J. vet. Res., **2**, 411-416, 1941.
3. Petkov, A. Anat. Anz., **119**, 177-187, 1966.
4. Amoroso, E. C. Placentation, in Marshall's Physiology of Reproduction, ed. by Parkes, A.S., **2**, 127-311. Longmans, Green and Co., London, 1952.
5. Hammond. J. The Physiology of Reproduction in the Cow. Cambridge at the Univ. Press, London, 1927.
6. Harvey, E.B. Implantation, Development of the Fetus and Fetal Membranes, in Reproduction in Domestic Animals ed. by Cole, H.H. and Cupps, P. T., **1**, 433-468, Academic Press, N.Y., 1959.
7. Dukes, H.H. The Physiology of Domestic Animals. Comstock Publ. Co., Inc., Ithaca, 1947.
8. Foley, R.C. and Reece, R.P. Bull. **468**, Agric. Exp. Sta., Univ. of Massachusetts, 1953.
9. Weeth, H.J. and Herman, H.A. Res. Bull. **501**, Agric. Exp. Sta.. Univ. of Missouri Coll. of Agric., 1952.
10. Wimsatt, W.A. Amer. J. Anat., **87**, 391-458, 1950.
11. Yamauchi, S., Kotera, K. and Kakishita, T. Jap. J. zootech. Sci., **39**, 487-504, 1968.
12. Cole, H.H. Amer. J. Anat., **46**, 261-301, 1930.
13. Weber, A.F., Morgan, B.B. and Mcnutt, S.H. Amer. J. Anat., **83**, 309-327, 1948.

NII-Electronic Library Service

Osaka Prefecture University

14. SKJERVEN, O. Acta endocr., Suppl. **26** (Vol. **22**), 1956.
15. JOHNSON, K.R. Res. Bull. **63**, Agric. Exp. Sta., Univ. of Idaho Coll. of Agric., 1965.
16. VOGEL, H.-J. Zbl. vet.-Med., A, **15**, 204-225, 1968.
17. MOSS, S., WRENN, T.R. and SYKES, J.F. Endocrinology, **55**, 261-273, 1954.
18. HORVATH, I. and KISZELY, Gy. Acta vet. Academicae Scientiarum Hungaricae, **9**, 27-37, 1959.
19. KINGMAN, H.E. Amer. J. vet. Res., **5**, 223-227, 1944.
20. ASDELL, S.A., DE ALBA, J. and ROBERTS, S.J. Cornell Vet., **39**, 389-402, 1949.
21. KLINGE, A. Zbl. vet.-Med., **6**, 742-780, 1959.
22. ASDELL, S.A Patterns of Mammalian Reproduction. 2nd Ed., Cornell Univ. Press, Ithaca, 1964.
23. BJÖRKMAN, N. Acta anat., Suppl. **22** (Vol. **22**), 1954.
24. BLANDAU, R.J. Anat. Rec., **103**, 19-47, 1949.
25. FOLEY, R.C., REECE, R.P. and LEATHEM, J.H. J. Anim. Sci., **13**, 131-137, 1954.
26. ALDEN, R.H. Anat. Rec., **97**, 1-19, 1947.
27. CHANG, M.C. Anat. Rec., **113**, 143-162, 1952.
28. MOSS, S., SYKES, J.F. and WRENN, T.R. J. Anim. Sci., **15**, 631-639, 1956.
29. SIMON, J. and MCNUTT, S.H. Amer. J. vet. Res., **18**, 241-245, 1957.
30. YAMAUCHI, S. Jap. J. vet. Sci., **26**, 107-114, 1964.
31. NELSON, W.O. Endocrinology, **24**, 50-54, 1939.
32. NELLOR, J.E. and BROWN, J.E. Anat. Rec., **155**, 591-602, 1966.

Explanation of Figures

Plate I

Fig. 5. No. 5 (A790), C.R.L. 9 cm. Pregnant horn. Morphological differences between superficial and basal glands are shown. ×48.

Fig. 6. No. 18 (A786), C.R.L. 16 cm. Non-pregnant horn. Neck segment of the gland penetrating the s. compactum is shown. ×48.

Fig. 7. No. 34 (A873), C.R.L. 26 cm. Non-pregnant horn. Both glands especially the basal glands are growing. Compare with preceding figures. ×48.

Fig. 8. Same as above. Contralateral horn. Many glands having an irregular outline are shown. ×48.

Fig. 9. No. 56 (B170), C.R.L. 60 cm. Non-pregnant horn. Basal glands are distinctly larger than before. Cyst-like gland is shown. ×48.

Plate II

Fig. 10. No. 58 (B163), C.R.L. 74 cm. Pregnant horn. Glands having a long-ellipsoid outline are shown. Identification of basal gland or superficial gland is difficult. ×48.

Fig. 11. Same as above. Contralateral horn. Irregularity in outline of glands is more prominent than in a pregnant horn. Branching of the gland is also noted. ×48.

Fig. 12. No. 5 (A790), C.R.L. 9 cm. Superficial gland in a pregnant horn. Epithelium consists of tall columnar cells which contain a few granules. Brush border is noted at the free margin. ×480.

Fig. 13. Same as above. Basal gland in a pregnant horn. Epithelium consists of low columnar cells. ×480.

Fig. 14. Same as above. Basal glands in a contralateral horn. Epithelium consists of cuboidal cells. Compare with Figs. 12 and 13. ×480.

Fig. 15. No. 18 (A786), C.R.L. 16 cm. Superficial gland in a pregnant horn. Granular cytoplasm and secretory feature are noted. ×480.

Fig. 16. Same as above. Superficial gland in a contralateral horn. Epithelial cells in less granularity than above are noted. ×480.

Plate III

Fig. 17. No. 34 (A873), C.R.L. 26 cm. Superficial gland in a non-pregnant horn. Luminal

NII-Electronic Library Service

Osaka Prefecture University

secretions as well as cytoplasmic processes are shown. ×480.

Fig. 18. Same as above. Basal gland in a contralateral horn. Luminal mass as well as epithelial secretion in apocrine type are shown. ×480.

Fig. 19. Same as above. Superficial gland in a contralateral horn. Columnar epithelial cells and secretory feature are shown. ×480.

Fig. 20. No. 56 (B170), C.R.L. 60 cm. Superficial gland in a pregnant horn. Decrease in height of the epithelium owing to the discharge of secretory materials is noted. Large quantity of secretions are noted in a lumen. Lymphocytes are shown intraepithelially and also in a luminal mass. ×480.

Fig. 21. Same as above. Basal gland in a pregnant horn. Cytoplasmic processes at the distal margin of the epithelium and it's granular cytoplasm are shown. ×480.

Fig. 22. Same as above. Superficial gland in a contralateral horn. Intense secretion is in progress. Lymphocytes are shown intraepithelially beside in a periglandular stromal tissue. ×480.

Fig. 23. Same as above. Basal gland in a contralateral horn. Luminal mass is shown. Periglandular capillary is noted. ×480.

Plate IV

Fig. 24. No. 58 (B163), C.R.L. 74 cm. Uterine gland in a pregnant horn. Difference in character of the gland between superficial and basal glands is not recognizable. Large quantity of the luminal mass is shown. Infiltration of lymphocytes is noted. ×480.

Fig. 25. Same as above. Uterine gland in a contralateral horn. Dark epithelium and a secretion in apocrine type are shown. ×480.

Fig. 26. No. 60 (B165), C.R.L. 76cm. Uterine gland in a pregnant horn. Tall epithelium and the cytoplamic processes are shown. ×480.

Fig. 27. Same as above. Uterine gland in a contralateral horn. Periglandular capillary is shown. ×480.

Fig. 28. No. 45 (B166). C.R.L. 39 cm. Superficial gland in a pregnant horn. A mitotic figure of the epithelial cell is noted. ×480.

Fig. 29. No. 1 (A750), C.R.L. 5 cm. Superficial gland in a non-pregnant horn. Desquamation of the epithelium is shown. Intense vacuolation of the epithelium is noted. ×480.

Fig. 30. No. 27 (A747), C.R.L. 22 cm. Superficial gland and it's opening in a non-pregnant horn. Slight desquamation of the gland epithelium is shown. The surface epithelium has been disappeared. ×240.

NII-Electronic Library Service

Osaka Prefecture University

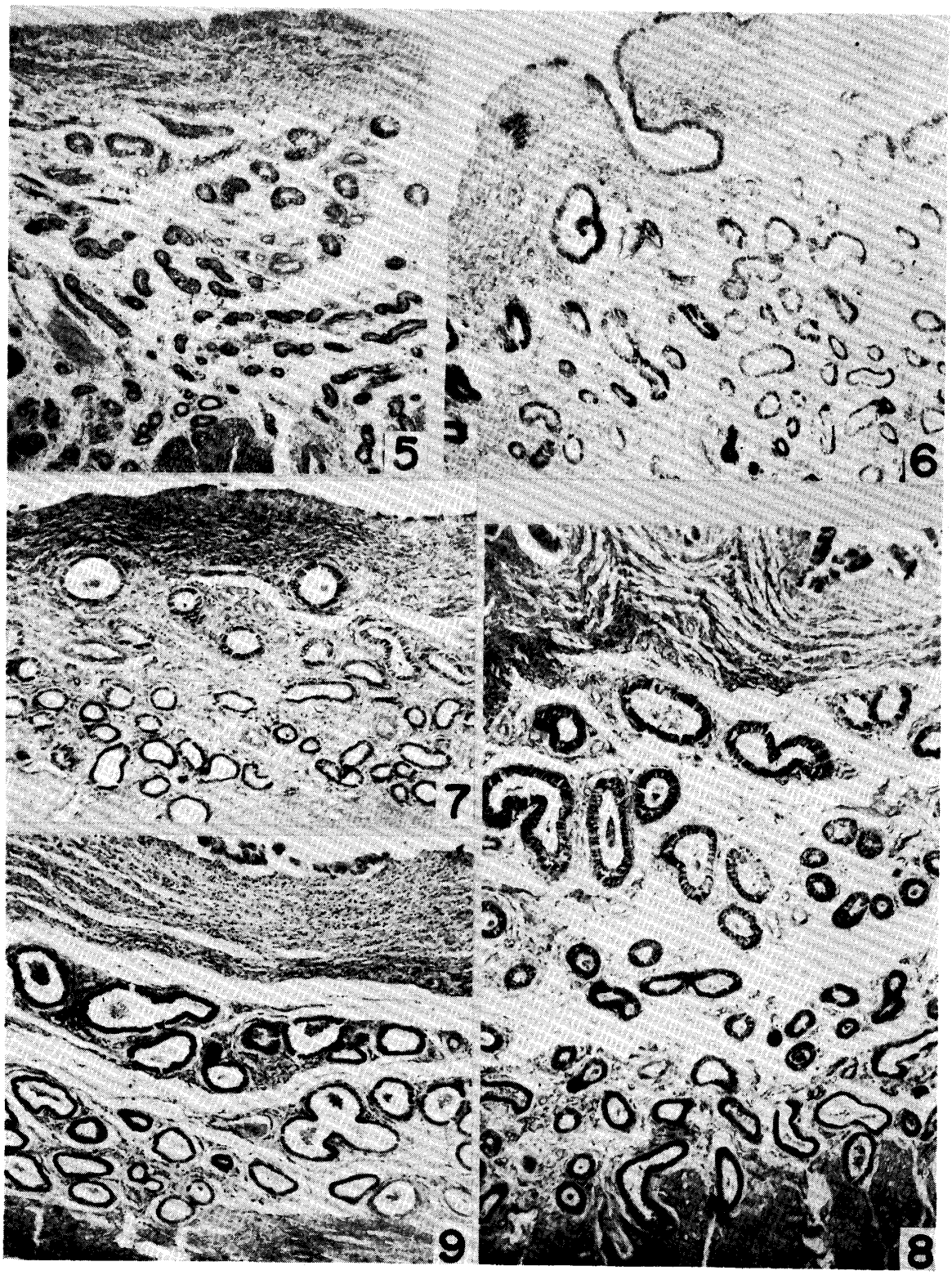

NII-Electronic Library Service

Osaka Prefecture University

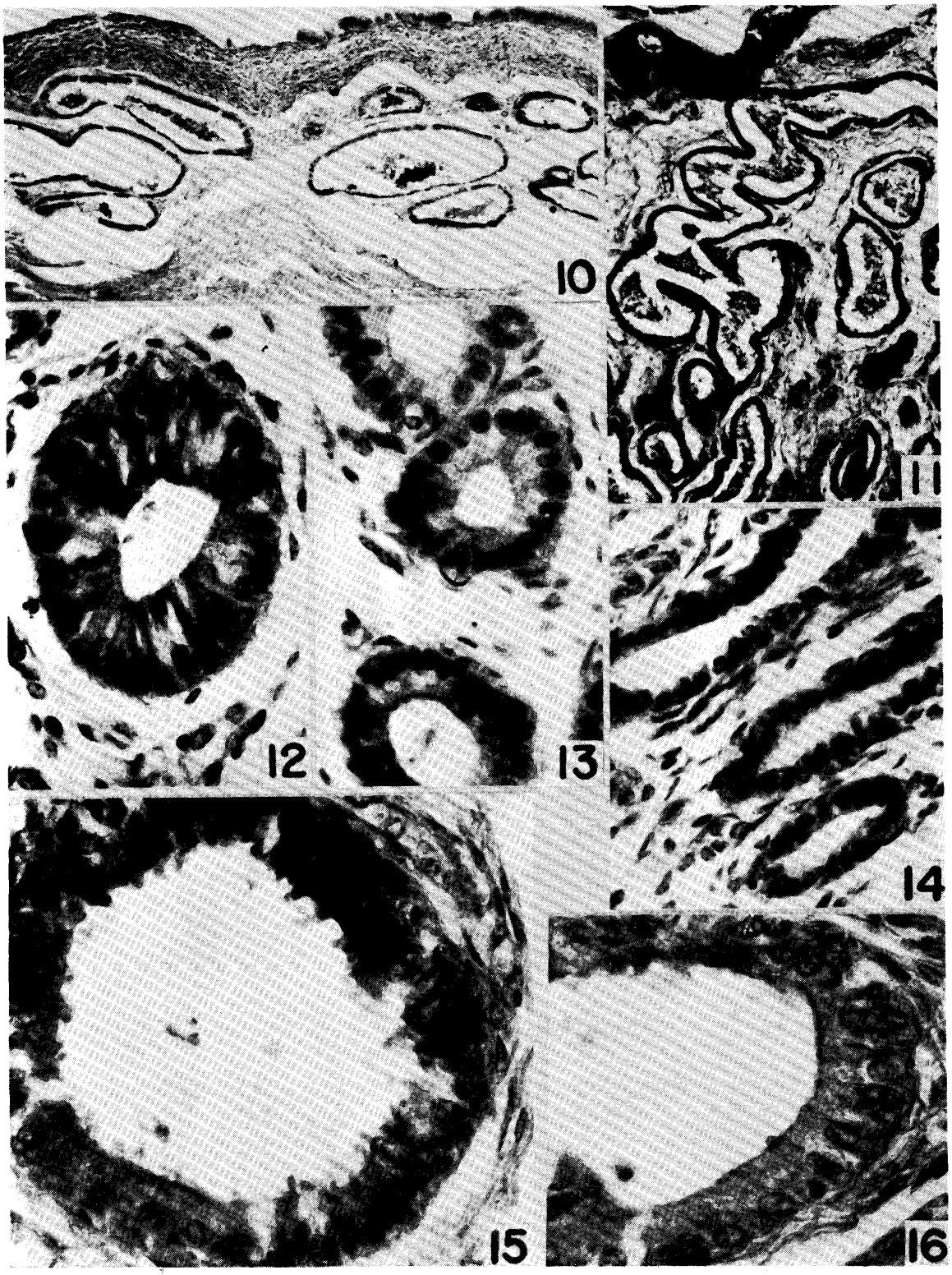

NII-Electronic Library Service

Osaka Prefecture University

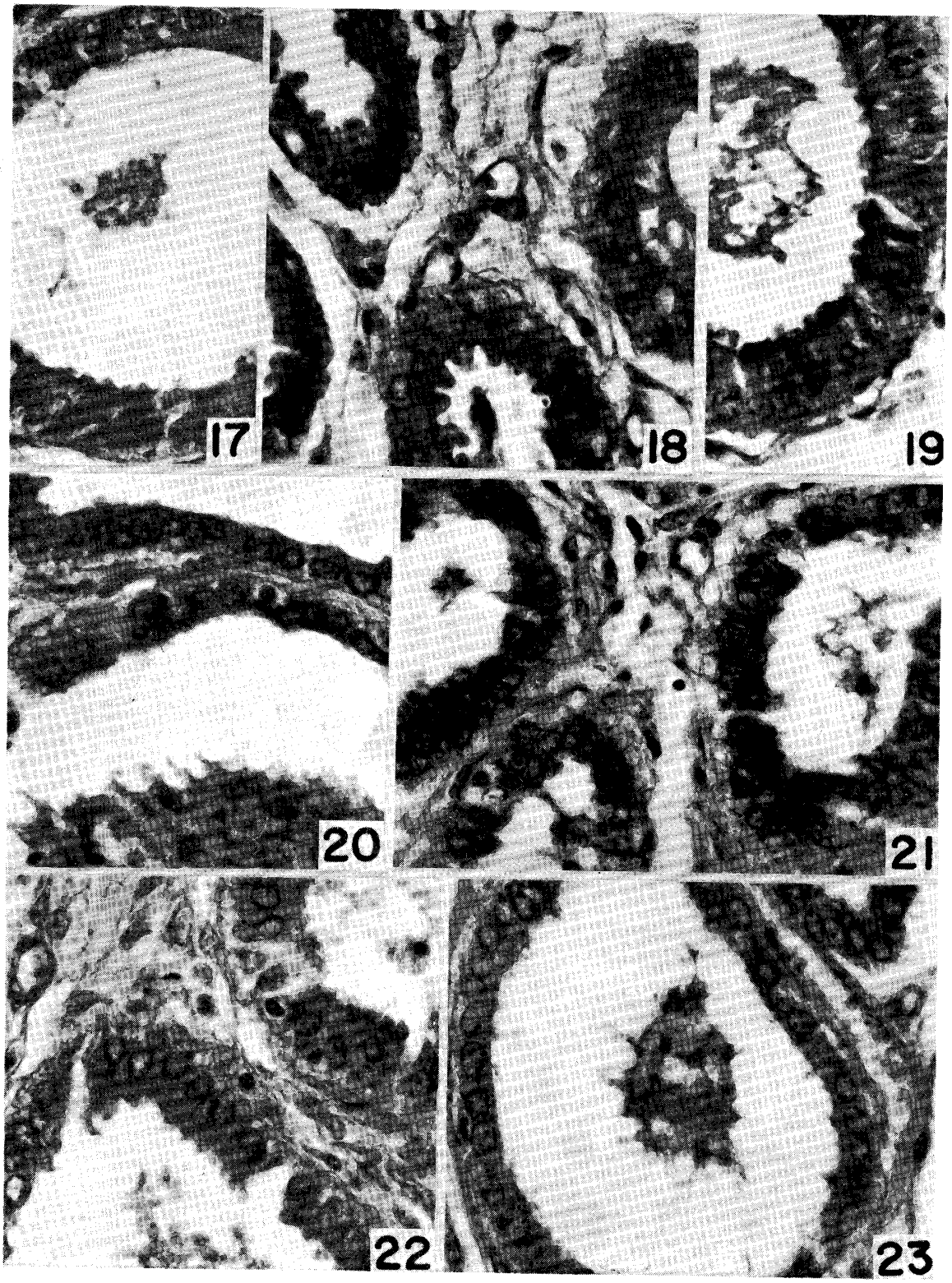

NII-Electronic Library Service

Osaka Prefecture University

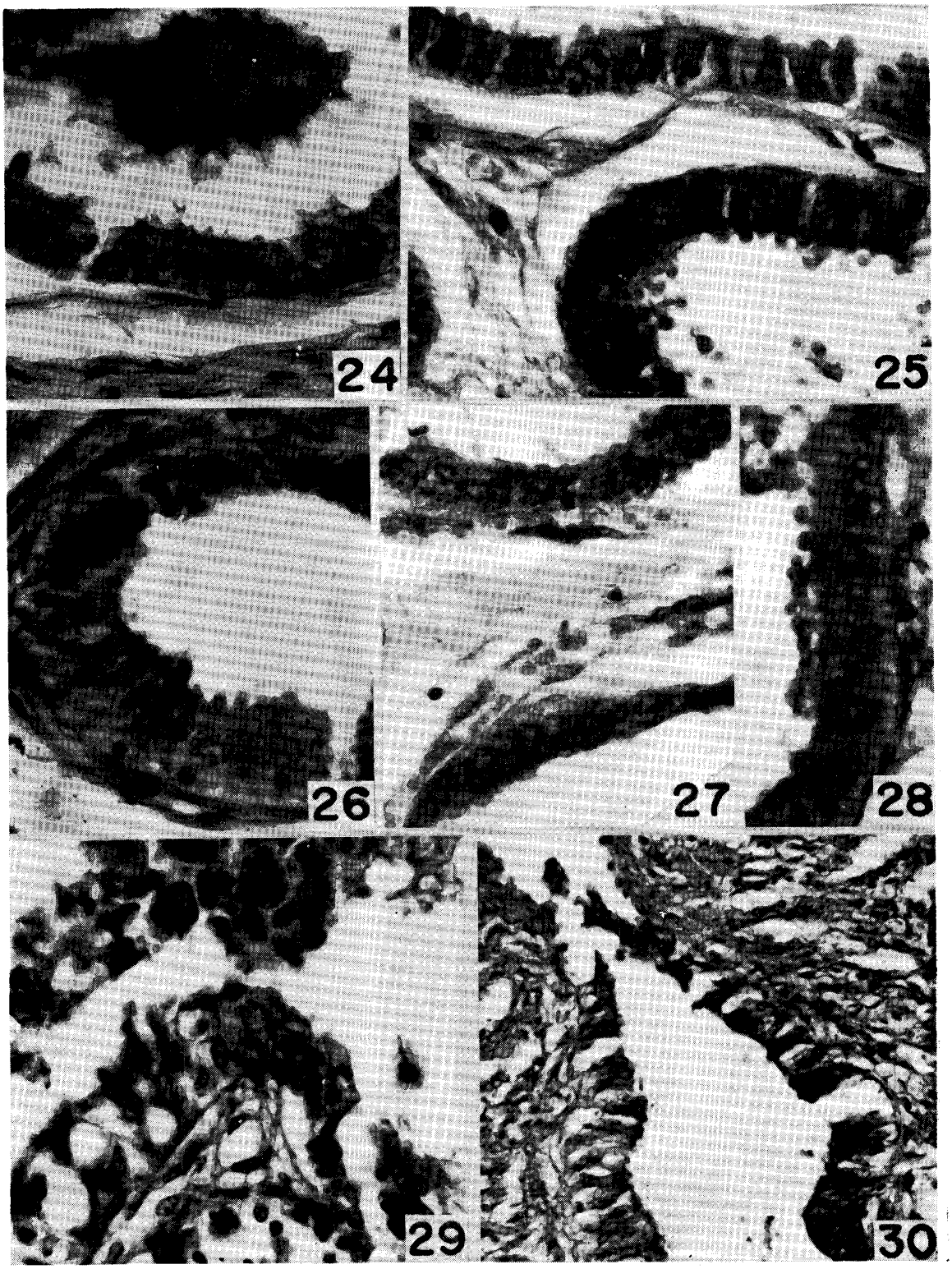

NII-Electronic Library Service